

# OCT and the Macula

Anthony DeWilde, OD

1

## OCT

Improve diagnosis

Determine referral

Patient education

2

58 year-old white male

C/O blur OS

"Things seem 'off'"

3

58 year-old

OD

OS

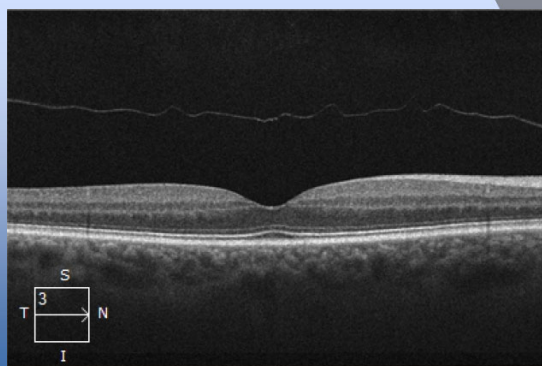
20/20

20/40

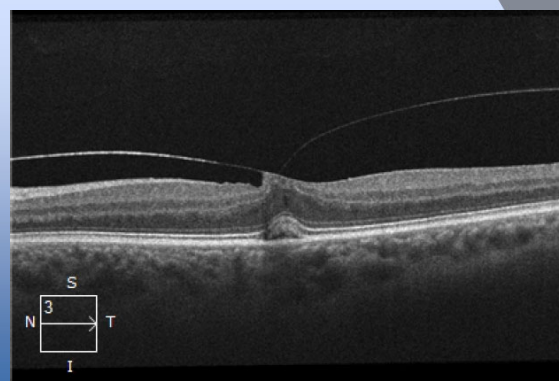
No systemic complications

Anterior segment normal

4




5



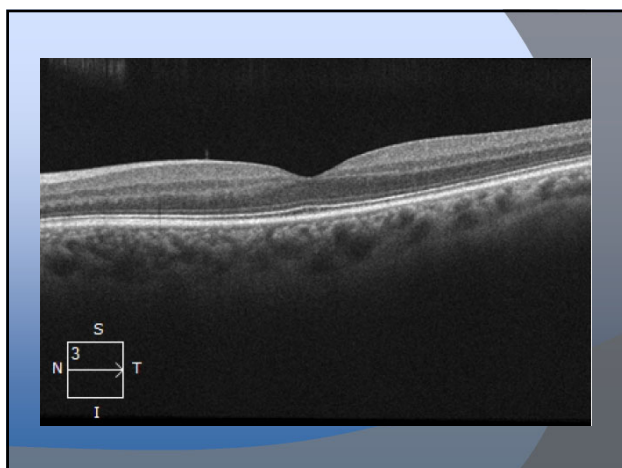
6



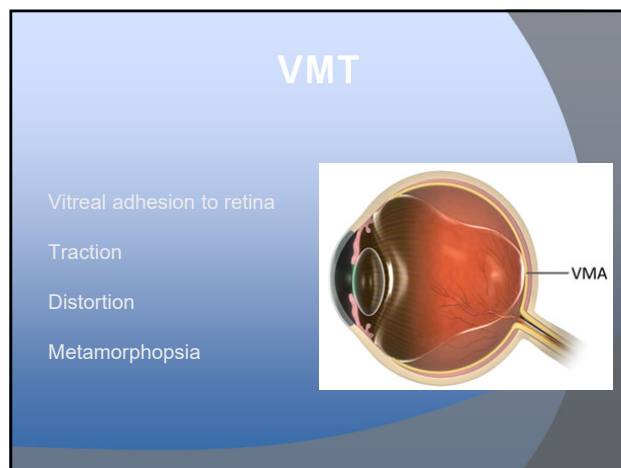
7



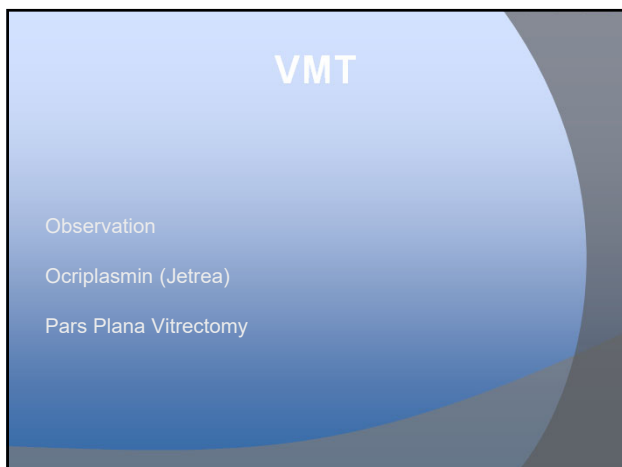
8



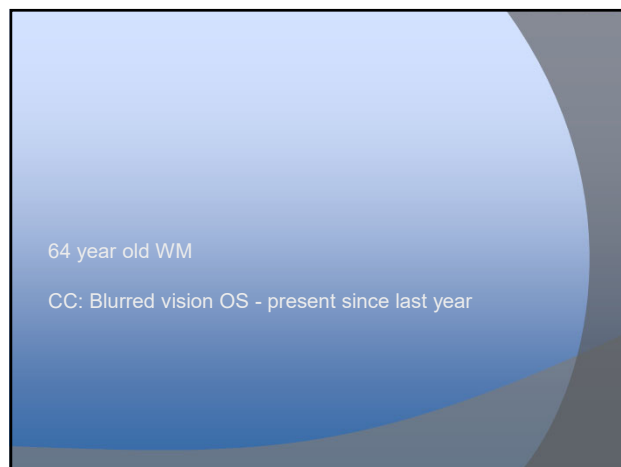
9



10



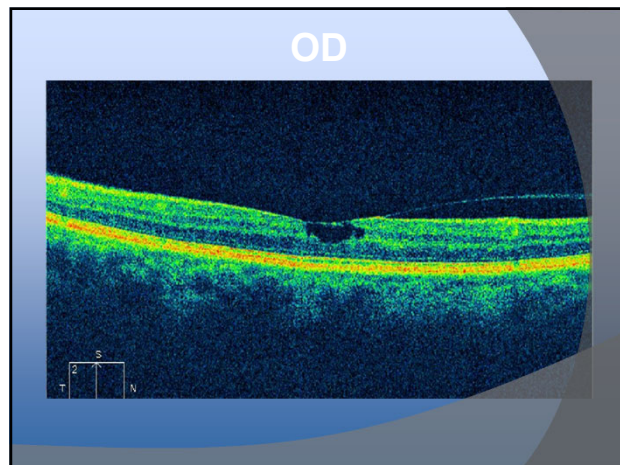
11



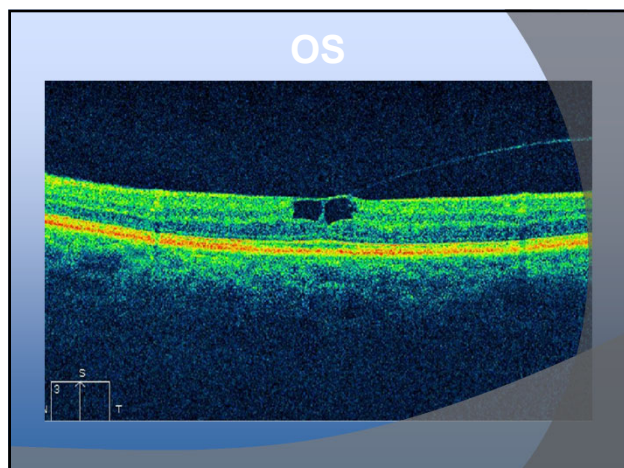
12

64 year-old White Male	
OD	OS
20/25	20/40
+DM, +HTN	
Anterior segment normal	

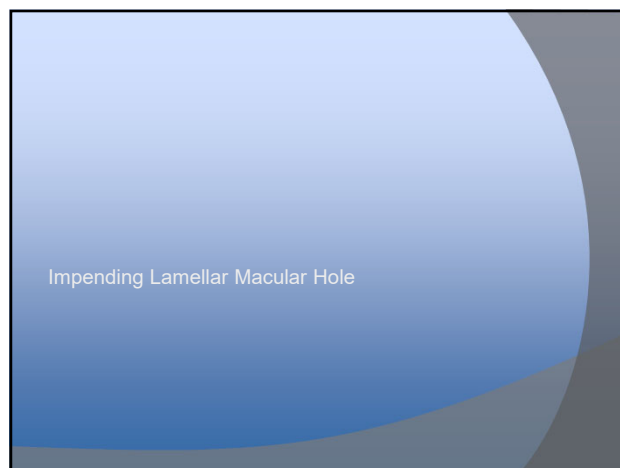
13



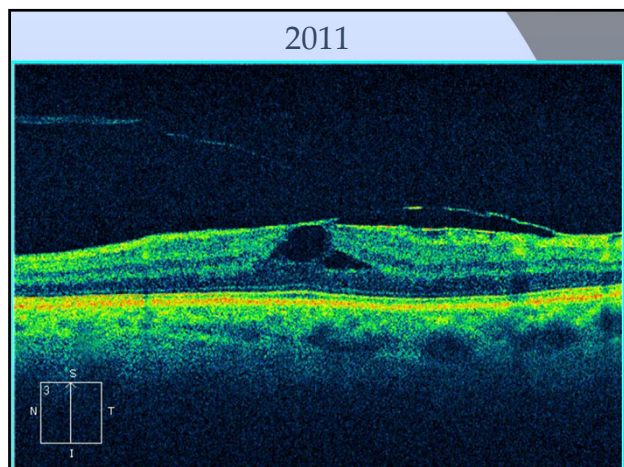
14



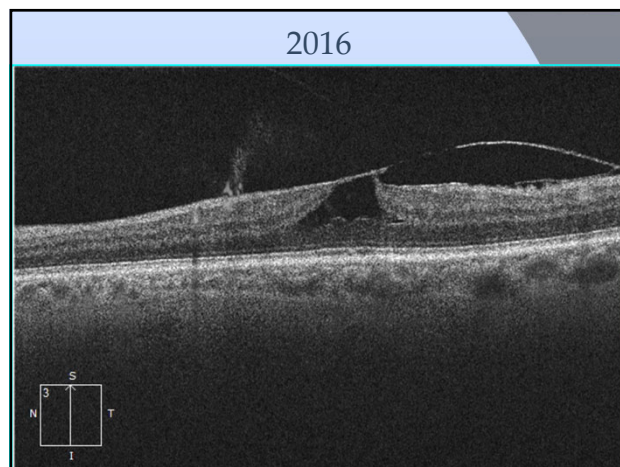
15



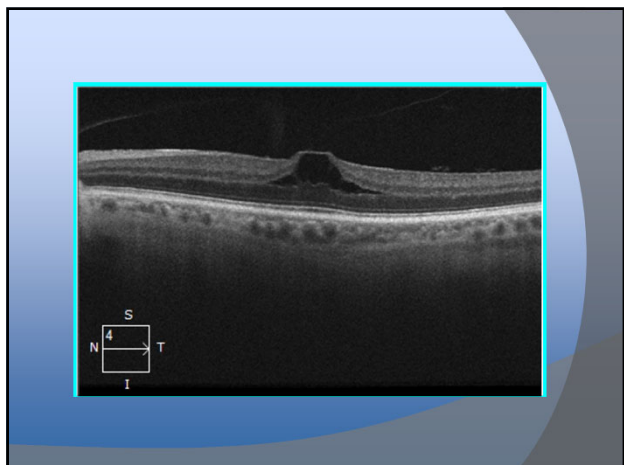
16



17



18



19

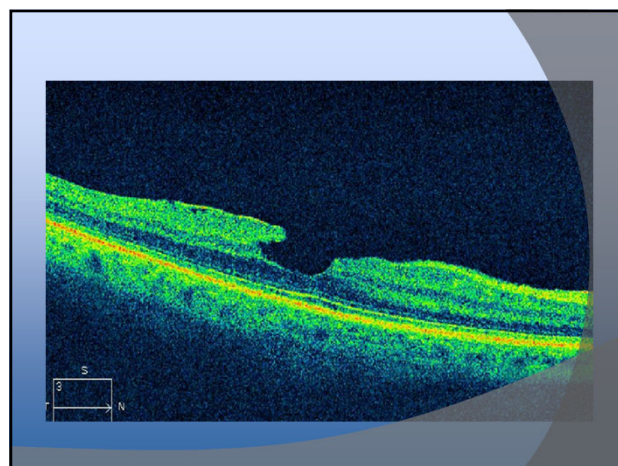
74 Y/O Hispanic Male  
 CC: Blurry vision when reading

20

74 year-old

OD	OS
20/40	20/25
+DM, +HTN	
Cataract OU	

21



22

Lamellar Macular Hole

23

Lamellar Macular Hole

Not full thickness  
 Atypical borders  
 "Inverted Anvil"

24

## Lamellar Macular Hole


Acuity typically better  
 Difficult to treat  
 Vitrectomy and Peel  
 May be more selective on when to treat

25

## Lamellar Macular Hole

Before OCT  
 Diagnosis less certain  
 Less known about Tx/prognosis

26



65 Y/O WM  
 Progressive blurring  
 Affecting golf, reading

27

7/2014

OD

OS

20/20

20/25

Normal Systemic Health

Bare Cataract OU

28

11/2014

OD

OS

20/20

20/50

ERM OS &gt; OD

Bare Cataract OU

29

02/2015

OD

OS

20/30

20/50

ERM OU

Bare Cataract OU

30

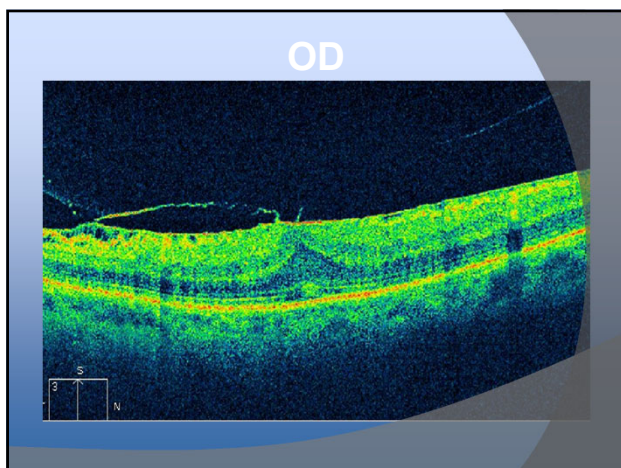
08/2015	
OD	OS
20/50	20/200
Moderate ERM OD, Severe ERM OS	
Bare Cataract OU	

31

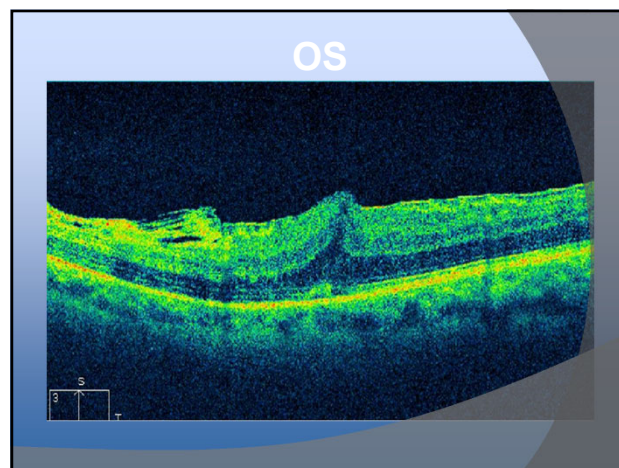
In 1 year from  
20/20 OD, 20/25 OS

To  
20/50 OD, 20/200 OS

32



33



34

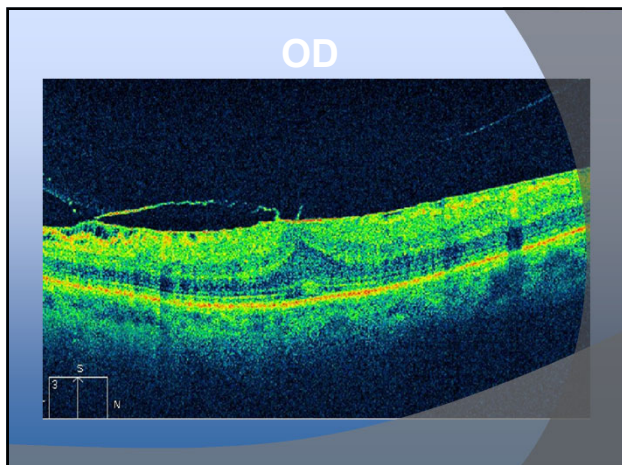
Refer to Retinal Specialist

Vitrectomy and ERM Peel OS (20/200)

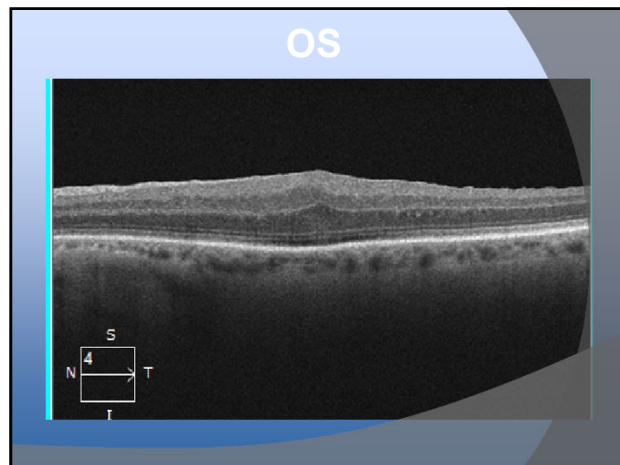
35

01/2016	
OD	OS
20/30	20/40
Moderate ERM OD, ERM Peel OS	
Mild Cataract OU	

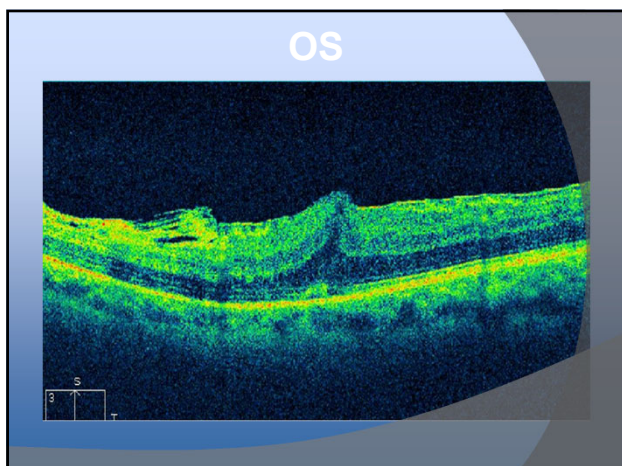
36



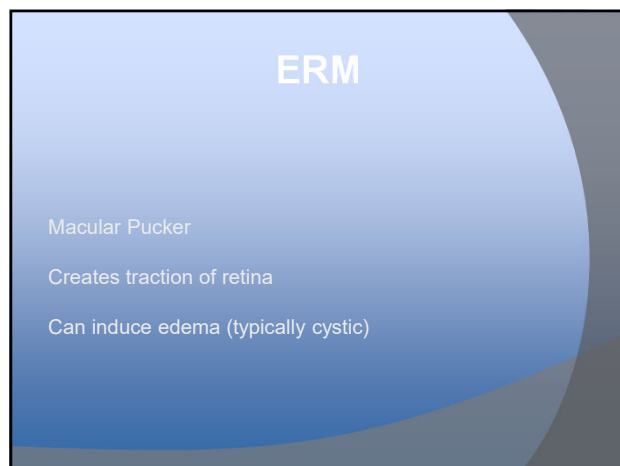
37



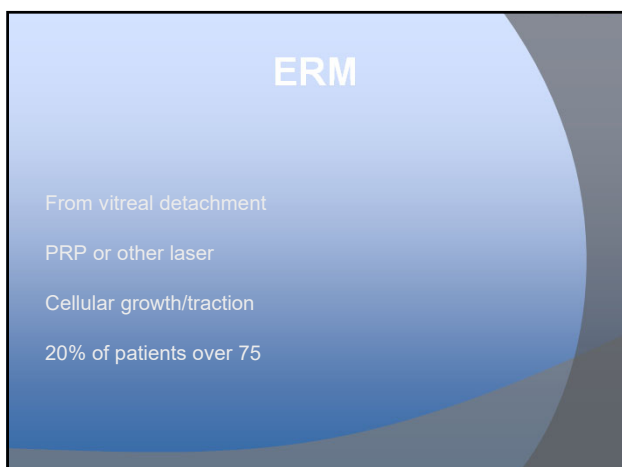
38



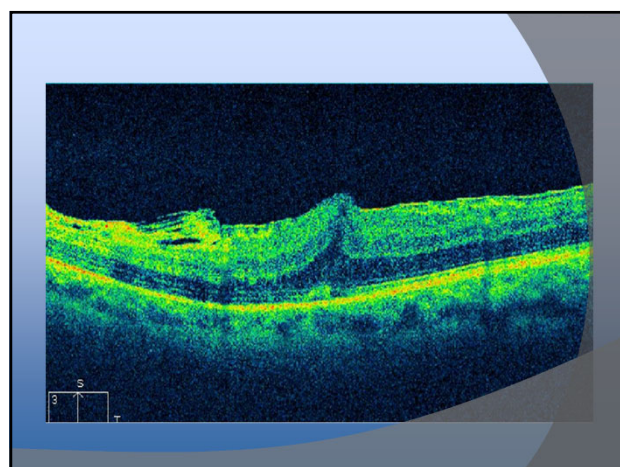
39



40



41



42

## ERM

Blur

Distortion

Metamorphosis

Range of acuity (20/20 - 20/400)

How many progress?

43

## ERM

Typically asymptomatic

If acuity reduced to  $\leq 20/40$ , treat

ILM peel

ERM peel

Vitrectomy

\*\*Cataract Surgery

44

75 year-old

OD

OS

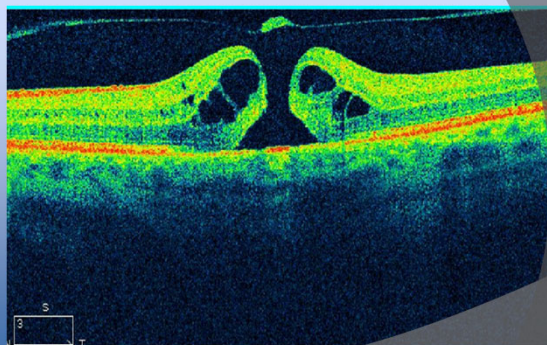
20/50

20/100

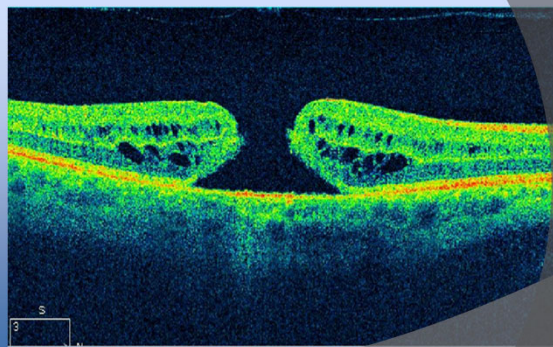
DM, HTN, COPD

Anterior Segment Normal - PCIOL OU

45



46



47

Bilateral macular hole

Patient elected to not have treatment

COPD

48

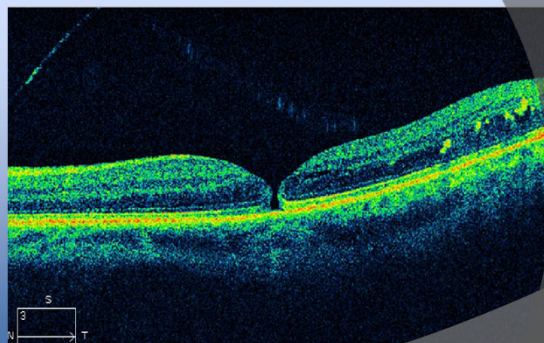


## Macular Hole

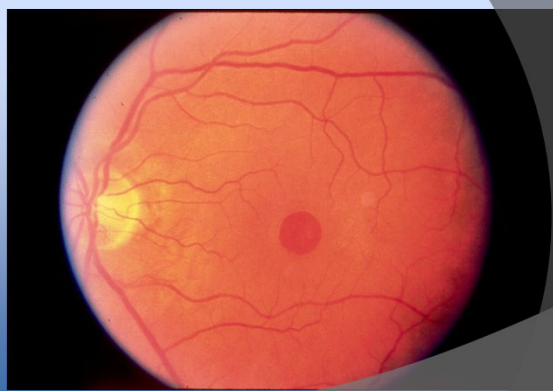
Full thickness retinal break

Acuity typically 20/100-20/200\*\*

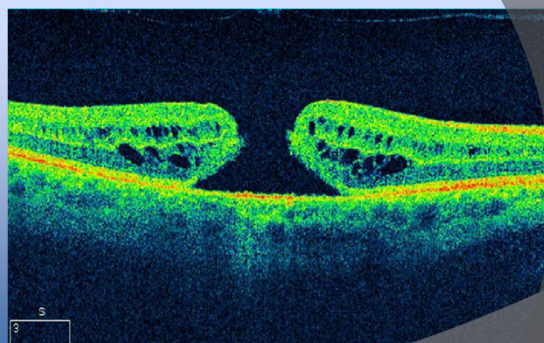
49



50



51



52

## Macular Hole

Treatment

Vitrectomy

Broad ILM peel

Fluid gas exchange

53

## Macular Hole

ILM Peel increases success from 90% -> 97%

54

## Macular Hole

### Complications

Cataract

Face down position

Lack of closure



55

## Macular Hole

### Modern Treatment

3 days mostly face down

Then sleep on side

56

## Macular Hole

### Modern Treatment

If concurrent cataract - treat first

Risk of CME disrupting outcome

57

## Macular Hole

ILM Peel with No Face-Down Positioning

*Ophthalmology 2013;120:1998-2003*

58

## Macular Hole

68 patients with idiopathic full thickness macular hole

Vitrectomy, ERM/ILM peel, SF<sub>6</sub>

Reading position post-op (3-5 days)

59

## Macular Hole

100% closure

Mean pre-op 20/100

Mean post-op 20/40

No complications

60

67 year-old Male	
OD	OS
20/40	20/30
Glaucoma	
PCIOL OD x 1 month, NS OS	

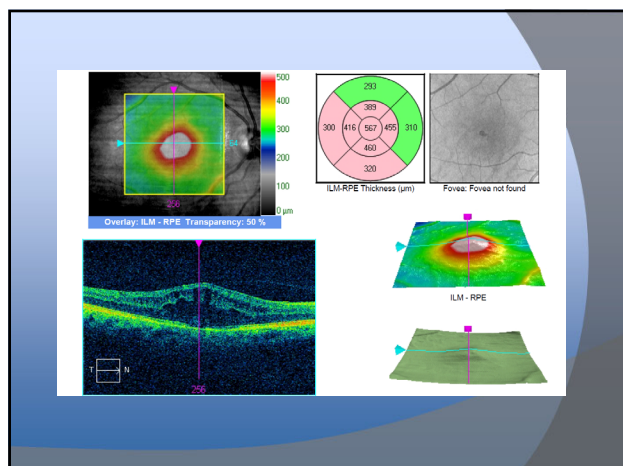
61

Anterior Segment

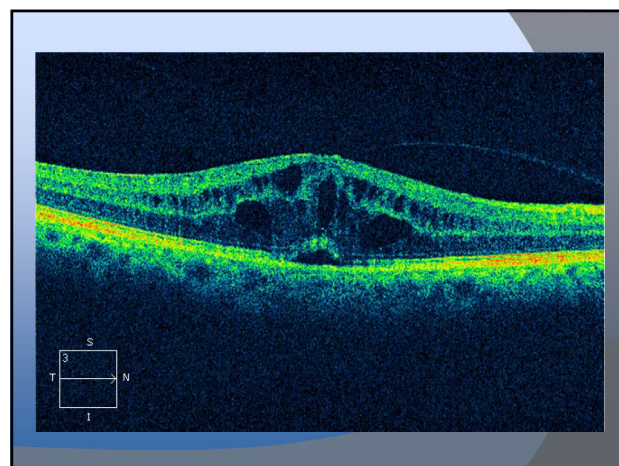
Trace Cell OD

Mild K Edema (Fuch's Dystrophy)

62



63



64

Irvine-Gass CME

Start Pred Forte QID

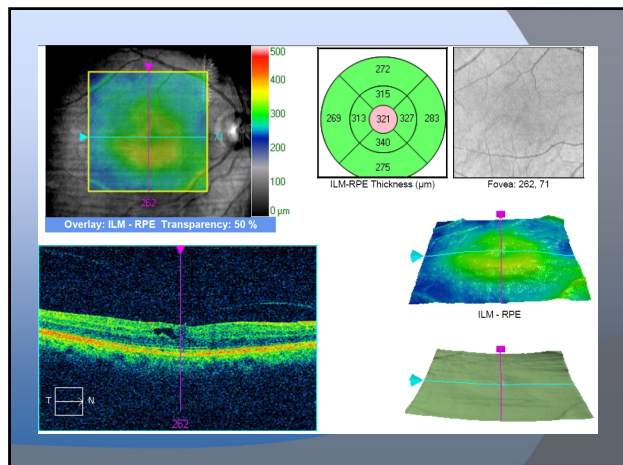
Diclofenac QID

65

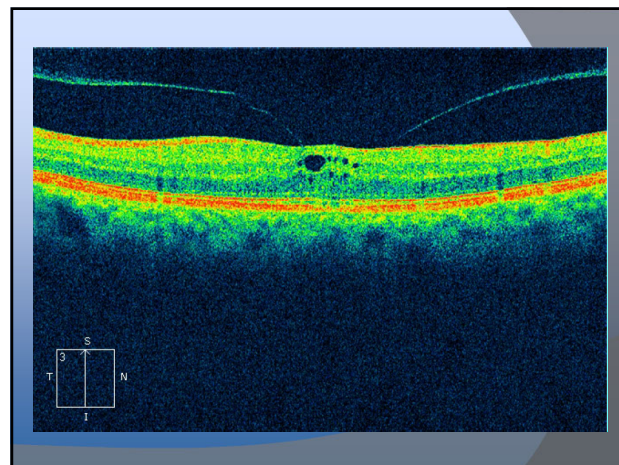
5 months later

20/20 OD and OS

66



67



68

## Irvine Gass CME

Need to define CME

Vein occlusion

ERM

RP

Diabetes

Post-op

69

## Irvine Gass CME

Pseudophakic cystoid macular edema

Up to 2.3% in phaco

More common in intracapsular/extracapsular

70

## Irvine Gass CME

Risk Factors

Posterior capsule rupture

IOL dislocation

Iris fixed IOL

ACIOL

71

## Irvine Gass CME

Very few cells in AC

72

## Irvine Gass CME

Treatment

Topical NSAID/Steroid QID\*

73

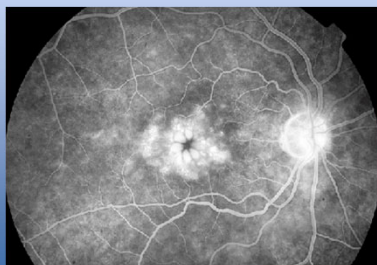
## Irvine Gass CME

Expect recovery over 3+ months

Generally follow at 6 week intervals

74

## Diabetic Macular Edema vs Irvine Gass CME



75

71 year old

Glaucoma follow up

Mild blur at near

76

IOP 8/10 on Latanoprost

NS OU

Anterior Segment normal

77

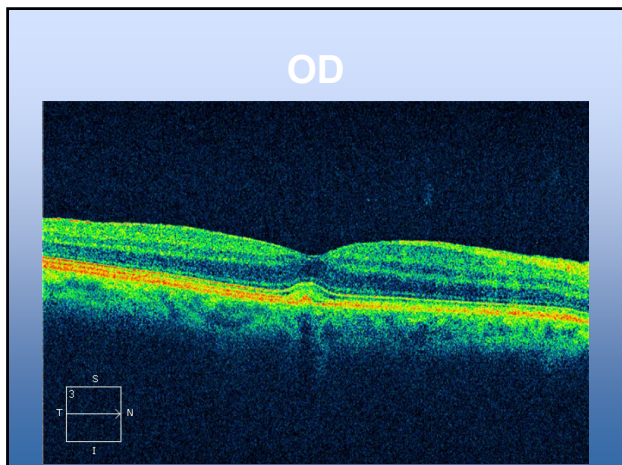
Posterior segment

Glaucoma

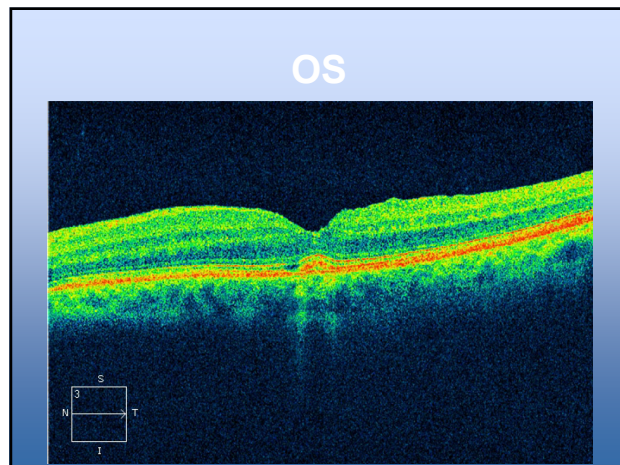
Normal vasculature

One small druse OU

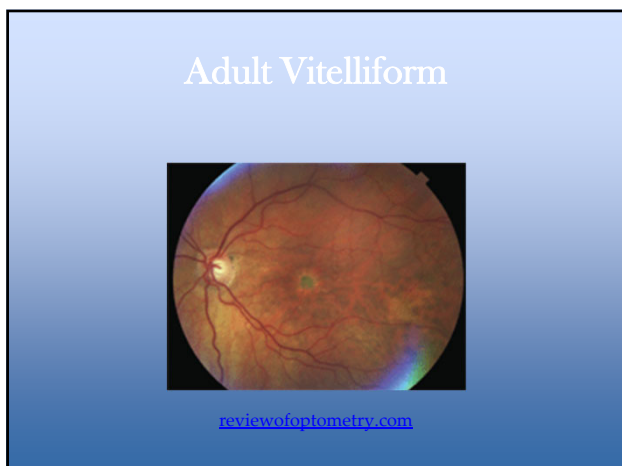
78



79



80



81

### Adult Vitelliform

- Similar to Best's
- Later in life
- Smaller lesions
- Less complications

82

### Adult Vitelliform

- Lipofuscin accumulation
- Between RPE and Photoreceptors
- 5-15% develop CNVM
- Typically mild and asymptomatic

Optometry (2006) 77, 156-166

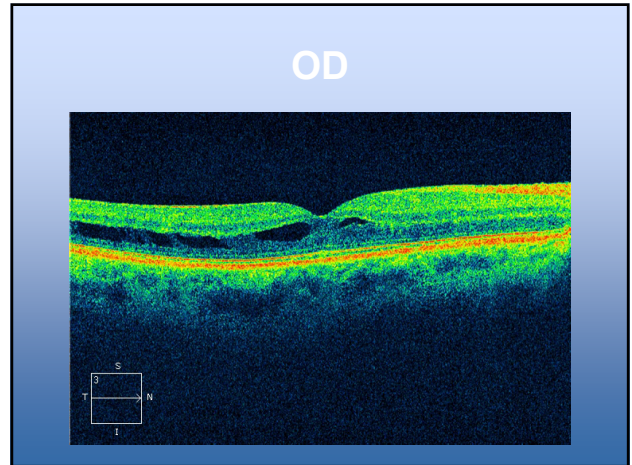
83

56 year-old Male	
OD	OS
20/20	20/20
PCIOL OU	
Vision fluctuates - Dry Eye OU	

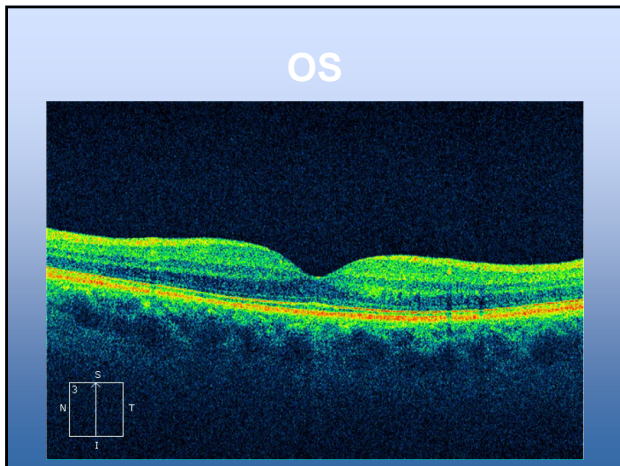
84

Posterior segment  
 Normal ONH  
 Normal vasculature  
 Macula abnormal

85



86

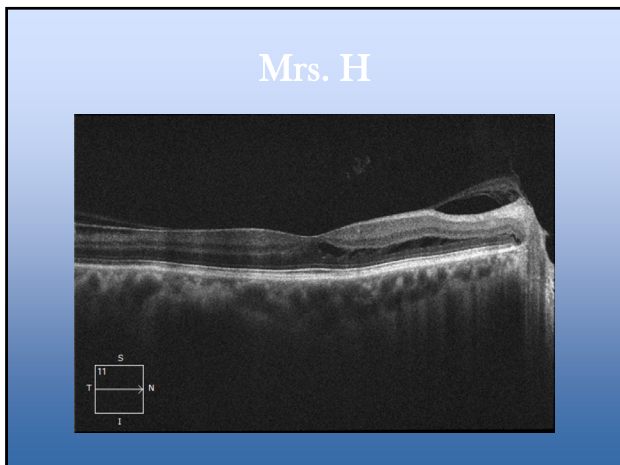


87

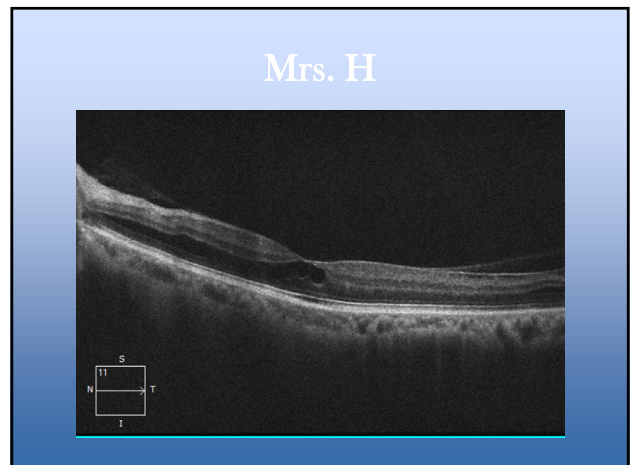
Juvenile Retinoschisis

Incidental finding  
 Patient asymptomatic  
 Treated with CAI (Trusopt) - no benefit

88



89

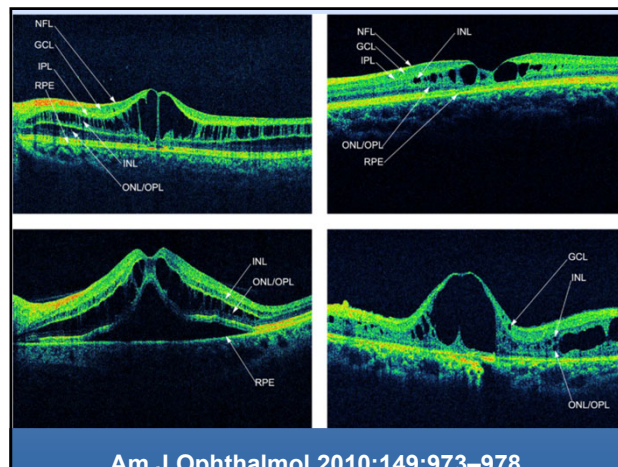


90

## Juvenile Retinoschisis

Genetic malformation (x-linked) - typically male  
 Difficult to diagnose funduscopically  
 Amblyopia masquerader

91

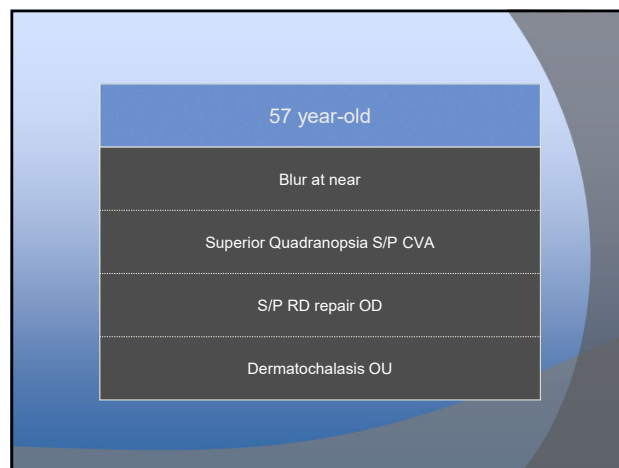


92

## Juvenile Retinoschisis

Variable layers affected  
 Variable appearance

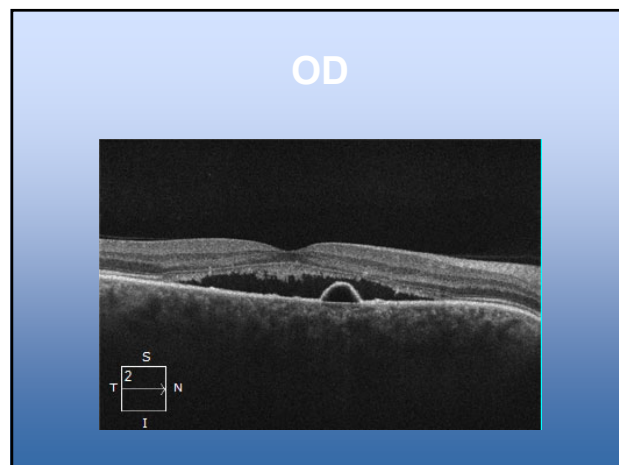
93



94

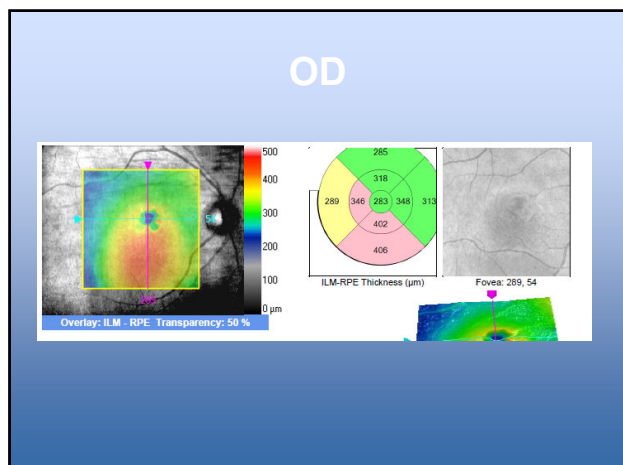
Posterior segment normal except  
 Macula OD has  
 Pigment changes  
 Serous elevation  
 Macula OS Normal!

95

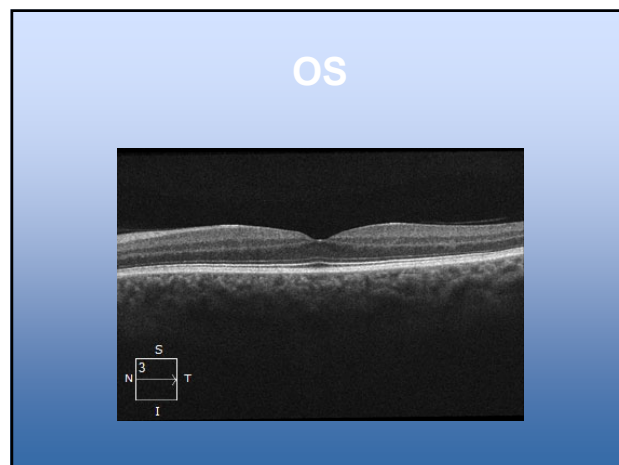


96

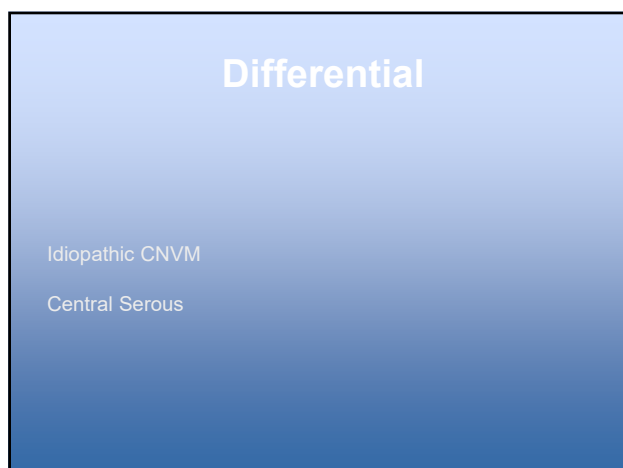




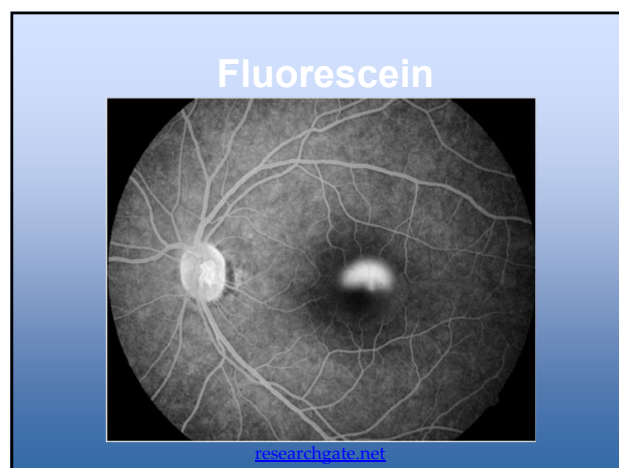
97



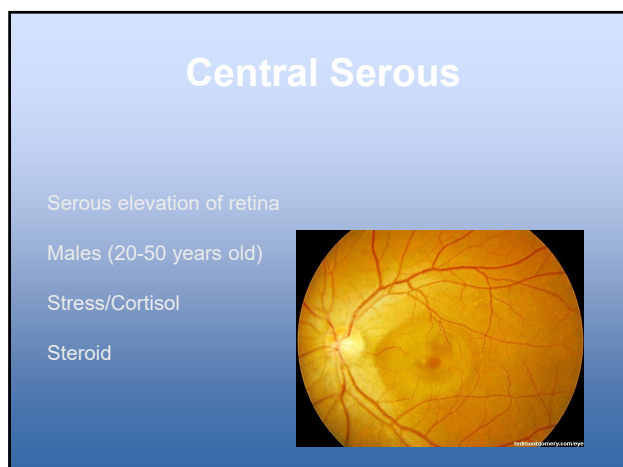
98



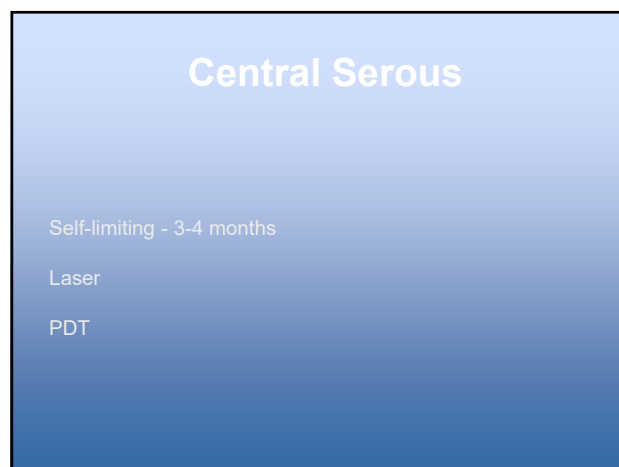
99



100



101



102

## Central Serous

30% can become chronic

Eplerenone

Spironolactone

103

48 year-old Male

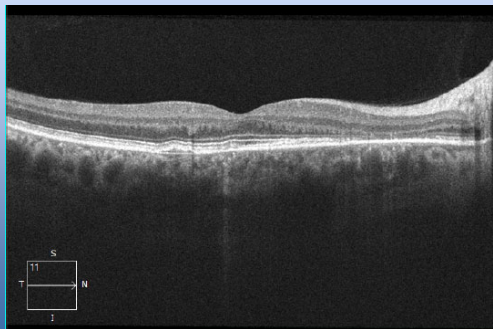
"Film over vision"

On Testosterone

Recent Steroid Injection

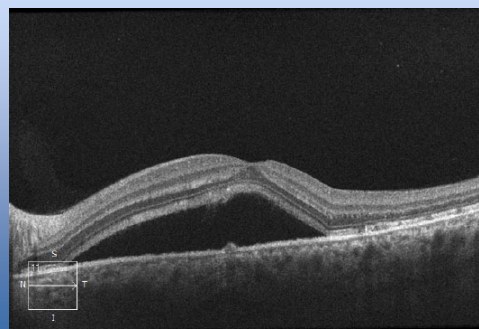
104

## OD - November



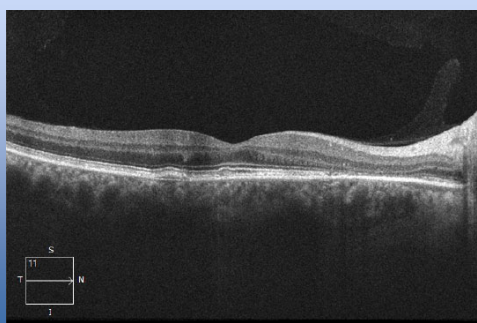
105

## OS - November



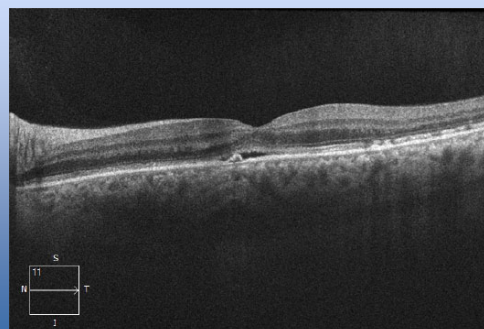
106

## OD - December

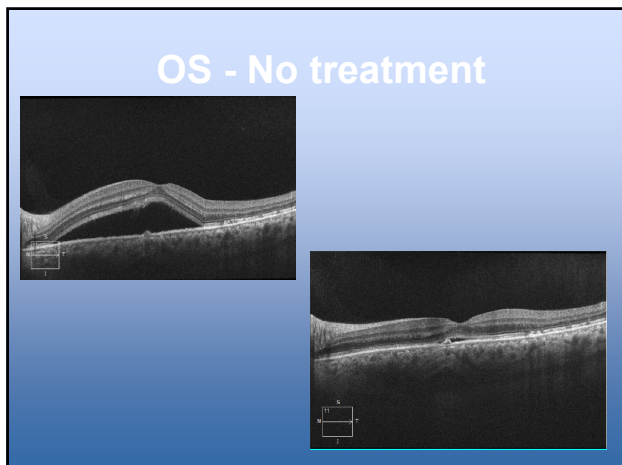


107

## OS - December



108

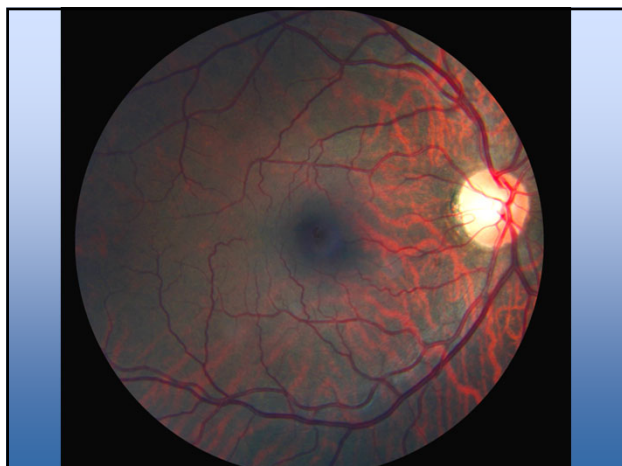

109

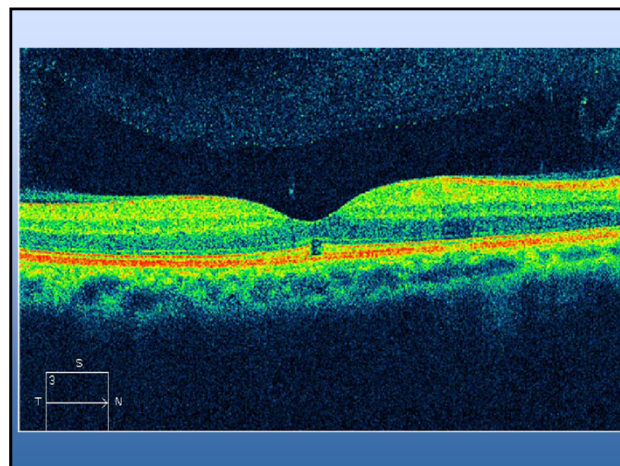
58 year-old Male

OD	OS
20/20	20/25
Blur at Near	
Anterior Segment Unremarkable	

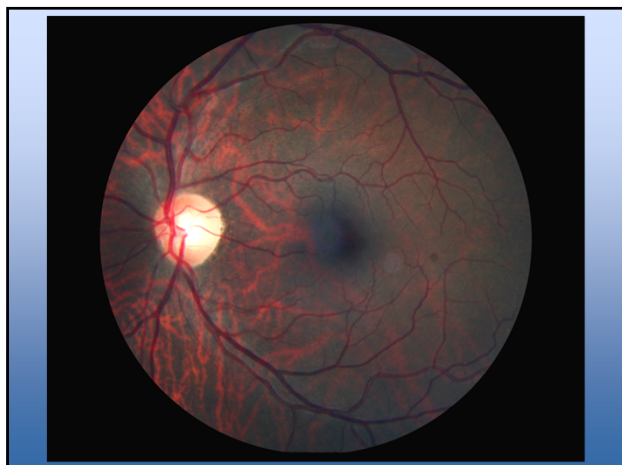
110



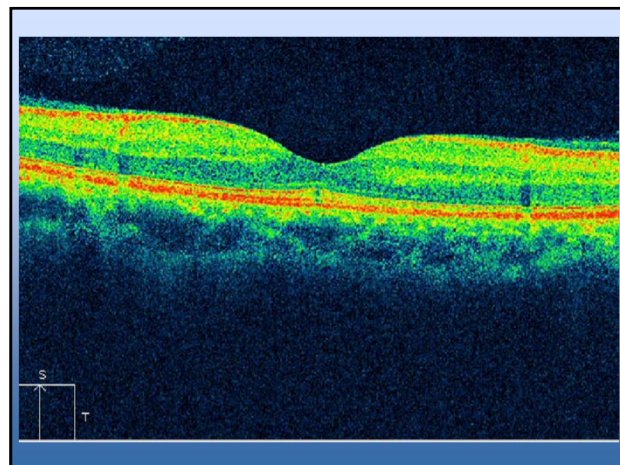
111



112



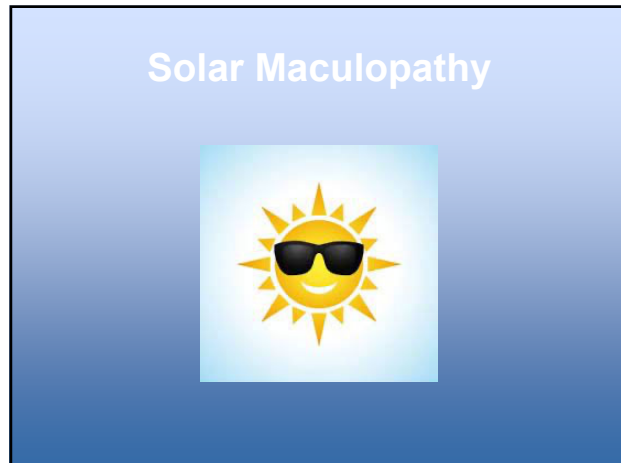
113



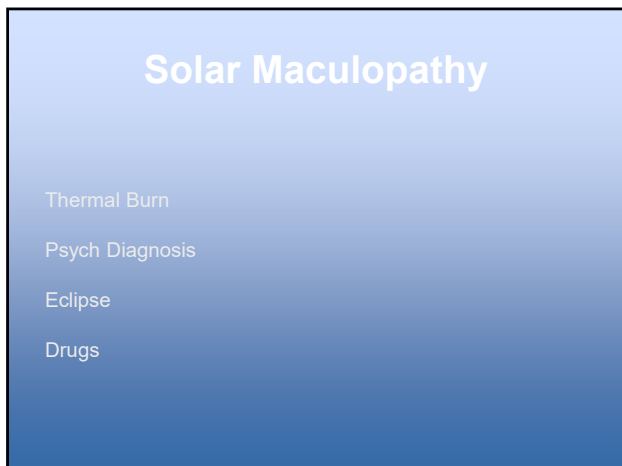
114



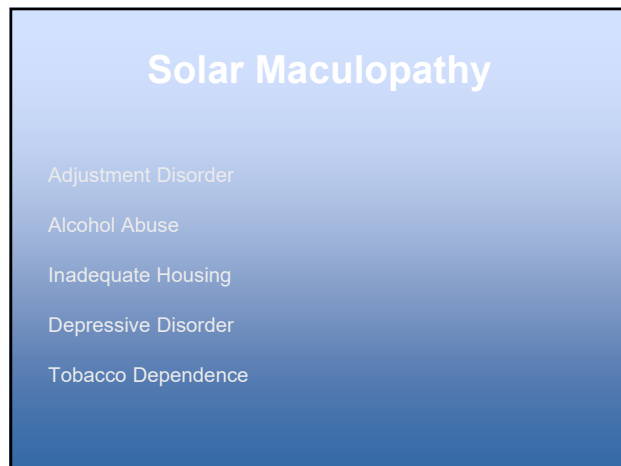
115



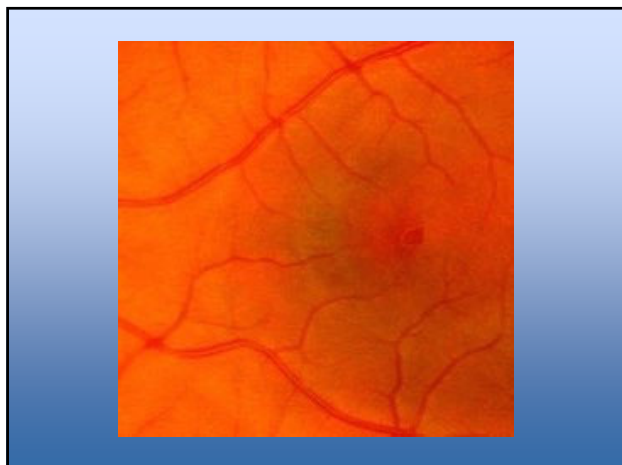
116



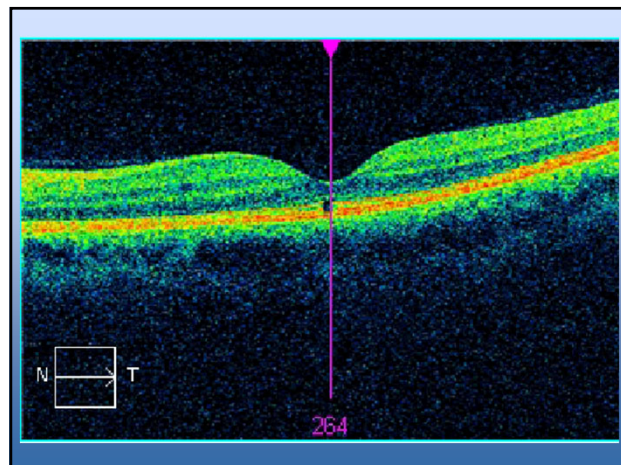
117



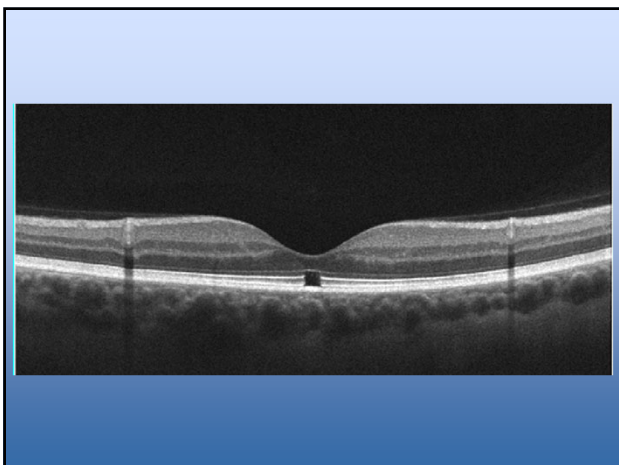
118



119



120



121

## Solar Maculopathy

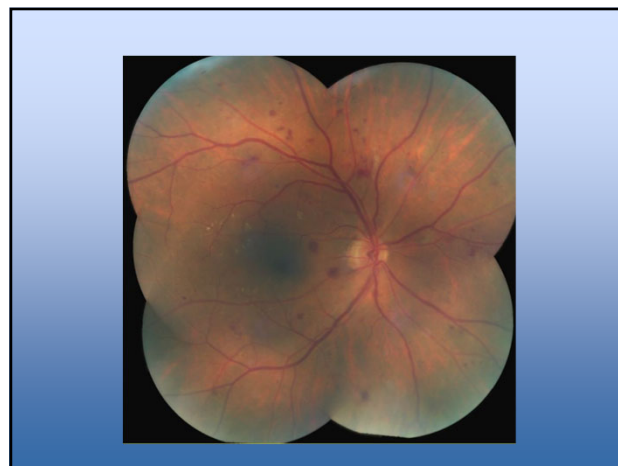No ocular treatment - non progressive

Mental health referral?

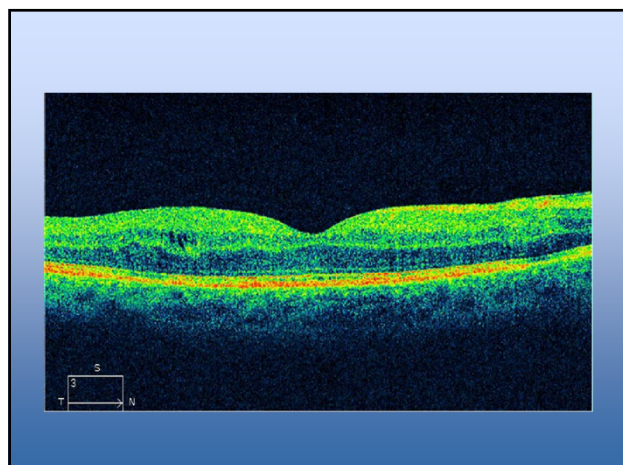
122

68 year-old
20/25 OD, 20/20 OS
+IDDM (A1c = 8), +HTN
No NVI
Cataract OU

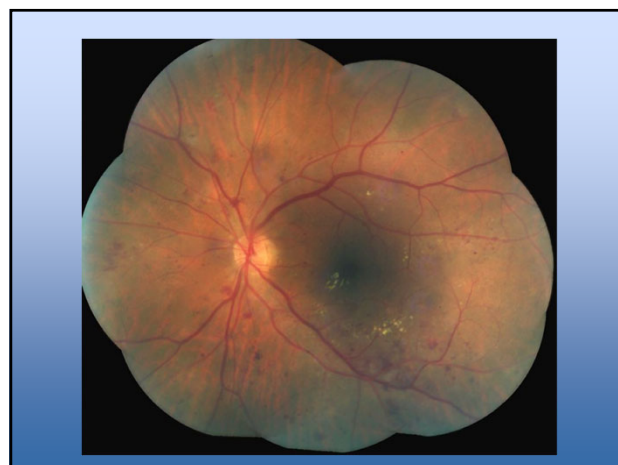123



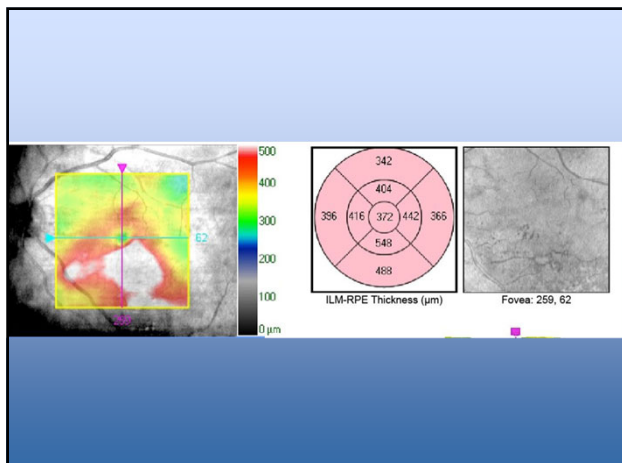
124



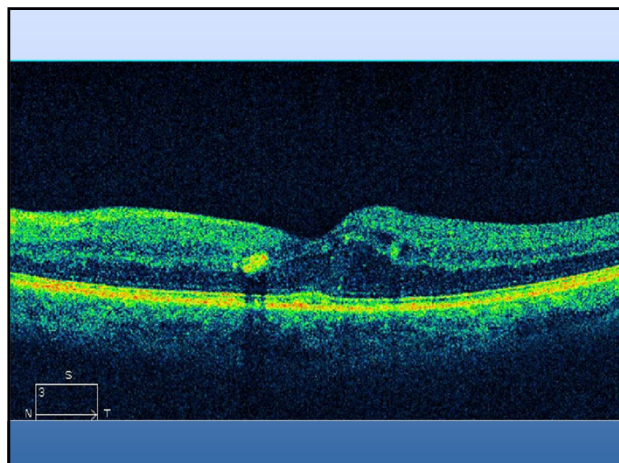
125



126



127



128

Diagnosis

NPDR OU

No CSME OD

CSME OS

129

### CSME

Retinal thickening 1 disc area – any part within 1 disc diameter of center of fovea

Hard exudates within 1/3 disc diameter of center of fovea with adjacent thickening

Retinal thickening within 1/3 disc diameter of center of fovea

130

### CI-DME

Treatment Criteria

Central retinal edema

$\leq 20/30$

131

Treatment

Prompt referral to retinal specialist

Under treatment with IVI Avastin

132

Prognosis?

133

How many injections are necessary?

134

81 year-old

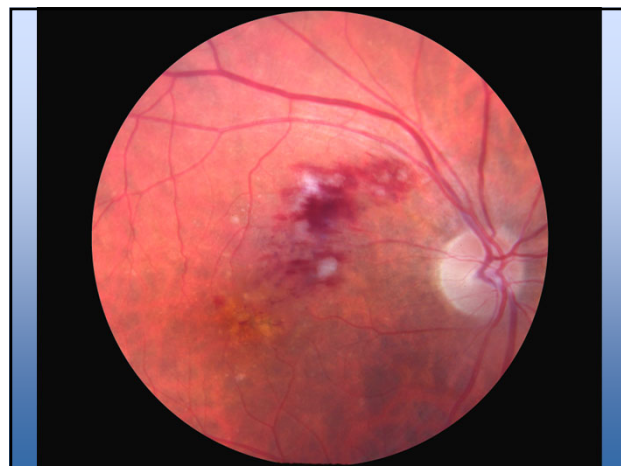
20/25 OD, 20/25 OS

Routine Exam

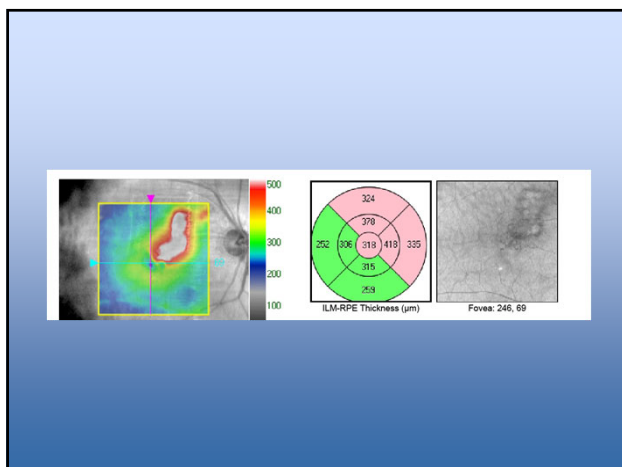
No Complaints

Mild Cataract OU

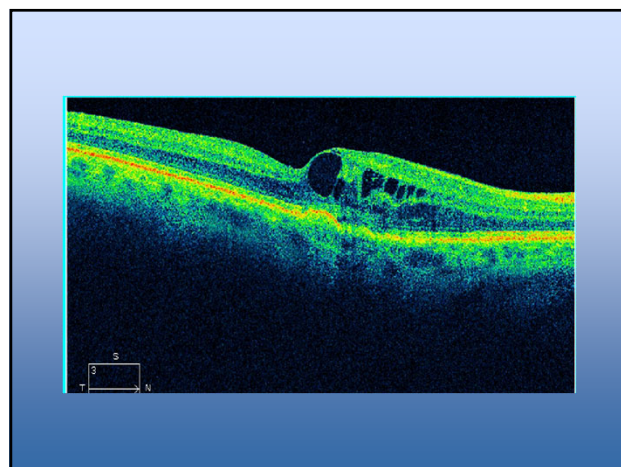
135



136



137



138

BRVO OD  
20/25 acuity  
Refer?

139

Historically treated with laser @ 3 months  
Now treated with Anti-VEGF injections

140

Prognosis?  
How many injections needed?

141

72 year-old

20/50 OD, 20/30 OS

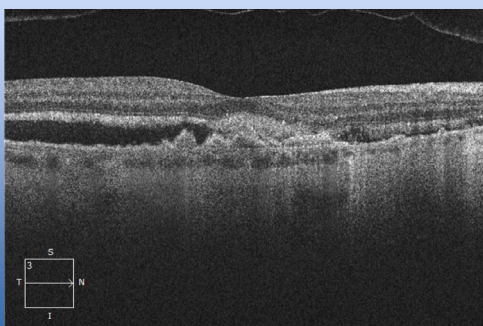C/O Difficulty Reading

PCIOL OU, AMD OU

IDDM, HTN

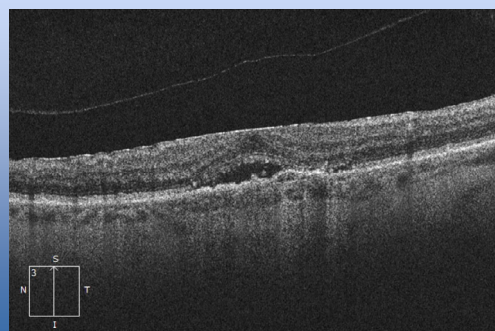
142

OD - 2016



143

OS - 2016



144



AMD OU

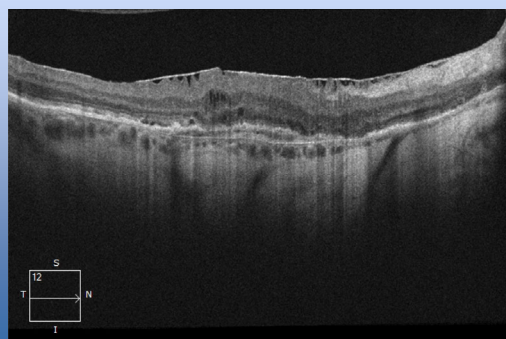
Serous elevation

Refer to retina

Intravitreal Anti-VEGF

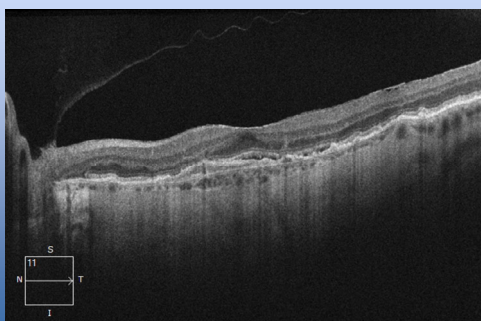
145

OD - 2018



146

OS - 2018



147

Vision

20/40

20/25

Can we expect better?

148

## Macular Degeneration

Four potential findings

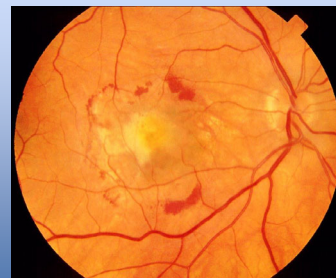
Sensory detachment

Pigment epithelium detachment (PED)

Sub-Retinal hemorrhage

Sub-RPE hemorrhage

149



150

## Macular Degeneration

Historically treated with

Nothing

Laser

Visudyne

151

## Studies

90% maintain acuity with treatment

Only 50% untreated maintain

152

## Studies

41% gained 3 lines of acuity with treatment

Only 6% untreated gained

153

## Studies

33-42% achieve 20/40 or better treated

Only 6% untreated reach 20/40

154

## Studies

Avastin = Lucentis = Eylea

Fewer injections with Eylea

11 vs 16 at 2 years

155

## Treat and Extend

Treat every month for 3 months

If stable, extend out

156

## Treat and Extend

90% had stability at 2 years  
45% had 20/40 acuity

Ophthalmology 2015;122:1212-1219

157

## Treat and Extend

Fewer injections (13 versus 17) - over 2 years  
Fewer Visits  
Less \$\$

158

[anthony.dewilde@va.gov](mailto:anthony.dewilde@va.gov)

159